



IMAGES IN INTENSIVE MEDICINE

A rare case of emphysematous osteomyelitis of spine in uncontrolled diabetes mellitus



Un raro caso de osteomielitis enfisematosa de la columna vertebral en la diabetes mellitus no controlada

S. Garg^a, M. Gupta^{a,*}, P.N. Choudhry^b

^a Department of Critical Care Medicine, Max Super Speciality Hospital, Vaishali, Ghaziabad 201012, India

^b Department of Internal Medicine, Max Super Speciality Hospital, Vaishali, Ghaziabad 201012, India

Available online 3 October 2018

A 65-year-old female admitted to the emergency department with complaints of severe back pain radiating to both lower limbs, high grade fever, nausea and vomiting since last 8–9 days. The patient had history of hypertension, diabetes mellitus and permanent pacemaker insertion 12 years back. Patient had no history of trauma or surgery. She had severe tenderness over the lower spine. No sensory or motor deficit could be elicited. Investigations showed leucocytosis, blood sugar of 665 mg/dL, HbA1C of 13.9% and procalcitonin of 39.24 ng/mL. Lumbar spine radiograph did not reveal any significant abnormality. CT lumbar spine revealed abnormal foci of intraosseous air in L5 and S1 vertebral bodies with associated pockets of air extending in bilateral pre and paravertebral soft tissue, in epidural space at L3 to S1 levels and along the sciatic nerve roots on both sides (Figs. 1 and 2). These findings represent emphysematous osteomyelitis. Patient was shifted to intensive care unit where broad spectrum antibiotics and other supportive care started. Blood and urine cultures reported *Klebsiella pneumoniae*, antibiotics reviewed as per sensitivity report. Orthopedic opinion sought and advised for biopsy and decompression surgery. Patient intubated in view of respiratory distress. She got shifted to another hospital on relative request where she underwent surgical decompression and drainage. Patient showed clinical improvement and discharged after 6 weeks.

Emphysematous osteomyelitis of spine is rare and is mostly associated with diabetes mellitus. Early diagnosis and aggressive surgical and medical management are crucial for patient outcome.

Acknowledgement

Authors wish to thank Critical care Team and Dr Ashok Grover (Senior Consultant, Internal medicine) for Support.

* Corresponding author.

E-mail address: drmanish2004@yahoo.co.in (M. Gupta).

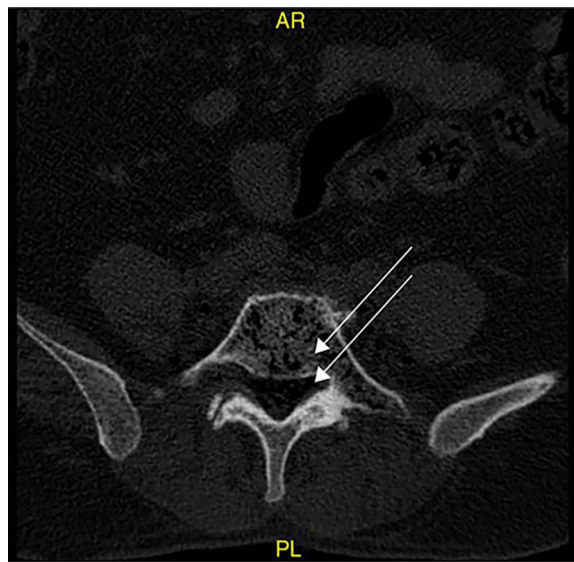


Figure 1 Axial view showing air pocket in vertebral body and epidural space.

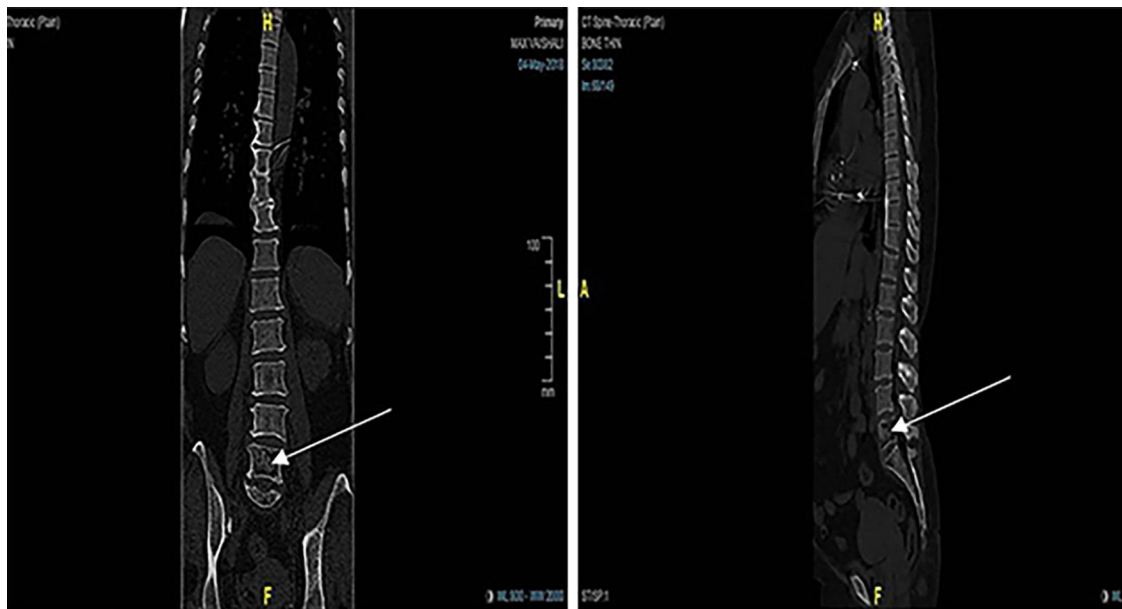

Figure 2 Coronal and sagittal view showing air pocket at L5-S1 vertebrae.