

- Spanish Apheresis Group. *Transfus Apher Sci.* 2013;49(3):560–4, <http://dx.doi.org/10.1016/j.transci.2013.09.008>.
5. Ahmed S, Kaplan A. Therapeutic plasma exchange using membrane plasma separation. *Clin J Am Soc Nephrol.* 2020;15(9):1364–70, <http://dx.doi.org/10.2215/CJN.12501019>.
 6. Gashti CN, Andreoli DC, Patel D. Membrane-based therapeutic plasma exchange (mTPE): technical and clinical experience. *J Clin Apher.* 2018;33(1):38–45, <http://dx.doi.org/10.1002/jca.21561>.
 7. Redant S, De Bels D, Ismaili K, Honoré PM. Membrane-based therapeutic plasma exchange in intensive care. *Blood Purif.* 2021;50(3):290–7, <http://dx.doi.org/10.1159/000510983>.
 8. Salazar Ramirez C, Daga Ruiz D, Cota Delgado F, Fernández Aguirre C, Fernández Añon JM, García Fernández JM. Utilidad de la plasmaféresis en cuidados intensivos [Utility of plasmapheresis in intensive care]. *Med Intensiva.* 2010;34(1):74–8, <http://dx.doi.org/10.1016/j.medin.2009.03.006>.
 9. Faria R, Bucur A, Gordinho A, Falcão L, Carrão A, Fernandes S, et al. Therapeutic plasmapheresis: seven year experience of an intensive care unit in Portugal. *Acta Med Port.* 2022;35(3):176–83, <http://dx.doi.org/10.20344/amp.14266>.
 10. Daga Ruiz D, Fonseca San Miguel F, González de Molina FJ, Úbeda-Iglesias A, Navas Pérez A, Jannone Forés R. Plasmapheresis and other extracorporeal filtration techniques in critical patients. *Med Intensiva.* 2017;41(3):174–87, <http://dx.doi.org/10.1016/j.medin.2016.10.005>.
- Á. Alonso-Ovies*, J. Álvarez Rodríguez
- Servicio de Medicina Intensiva, Hospital Universitario de Fuenlabrada, Fuenlabrada, Spain*
- Corresponding author.
E-mail address: a.alonso@salud.madrid.org
(Á. Alonso-Ovies).

Á. Alonso-Ovies*, J. Álvarez Rodríguez

Servicio de Medicina Intensiva, Hospital Universitario de Fuenlabrada, Fuenlabrada, Spain

Corresponding author.

E-mail address: a.alonso@salud.madrid.org

(Á. Alonso-Ovies).

2173-5727/ © 2022 Published by Elsevier España, S.L.U.

Early lung autopsy in deceased patients with acute respiratory distress syndrome due to infection by SARS-CoV-2



Autopsia pulmonar precoz en pacientes fallecidos con síndrome de distrés respiratorio agudo secundario a infección por SARS-CoV-2

The SARS-CoV-2 pandemic brought us a new plethora of patients with an extremely severe form of acute respiratory distress syndrome (ARDS).

Clinical autopsy can provide us with information to know and understand this new viral infection. The objective of this study is to characterize—at pulmonary level—the pathological anatomy (PA), microbiology, and viral load of a series of patients who died of SARS-CoV-2 related ARDS.

This was an observational prospective study of patients who had died at the intensive care unit (ICU) (teaching hospital; reference center for patients with SARS-CoV-2 infection) with a confirmed diagnosis of SARS-CoV-2 infection. The study was approved by the Spanish hospital ethics research committee (ASSE 2015). Informed consent from the closest family member was required.

Patients with ARDS (Berlin Definition)¹ due to SARS-CoV-2 infection (December 2020 through November 2021) were included.

The main clinical characteristics are shown on [Table 1](#) and the electronic supplementary data (ESD) Patients were categorized based on their ICU stay into 3 timeframes (up to 10 days, 11–20 days, over 20 days) based on the evolutionary stages of ARDS.²

Autopsies were performed 3 h prior to death to preserve the quality of microbiological samples. A macroscopic study of the lung was conducted and samples from the most compromised areas were drawn including microbiological (Gram staining, cultures, and mycological study),

and histological analyses (hematoxylin/eosin staining) using Masson’s Trichome Staining to rule out fibrosis and thrombosis. Viral analysis through RNA extraction, and viral genome

Table 1 General characteristics of the population (N = 21).

<i>Demographic characteristics</i>	N = 21
Age (years), mean (SD)	62 ± 12
Sex, feminine, n (%)	6 (29)
<i>Comorbidities</i>	
COPD, n (%)	8 (38)
AHT, n (%)	10 (48)
Diabetes, n (%)	4 (19)
Obesity, n (%)	8 (38)
<i>Variables on day 1</i>	
APACHE II, mean (SD)	21 ± 9
SOFA ESCORE, mean (SD)	12 ± 3
D-dimer (ng/mL), mean (SD)	13,164 ± 17,718
Ferritin (ng/mL), mean (SD)	2448 ± 1329
CRP (mg/L), mean (SD)	175 ± 89
LDH (U/L), mean (SD)	849 ± 432
Lymphocytes/mm ³ , mean (SD)	631 ± 427
<i>Organ dysfunctions</i>	
Circulatory shock, n (%)	17 (85)
AKI, n (%)	11 (55)
<i>Cause of death</i>	
Multiple organ failure, n (%)	4 (19)
Refractory hypoxemia, n (%)	9 (43)
Circulatory shock, n (%)	8 (38)
<i>Days on mechanical ventilation, mean (SD)</i>	15 ± 10
<i>ICU stay (days), mean (SD)</i>	17 ± 10

AHT, arterial hypertension; AKI, acute kidney injury; APACHE II, Acute Physiology and Chronic Health Evaluation II; COPD, chronic obstructive pulmonary disease; CRP, C-reactive protein; LDH, lactate dehydrogenase; SOFA, Sequential Organ Failure Assessment.

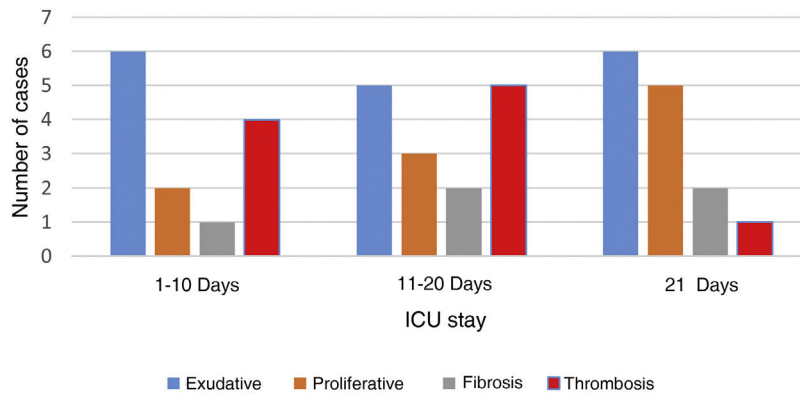


Figure 1 Different patterns shown depending on the ICU stay. In each case more than 1 anatomopathological pattern may have coexisted.

quantification (RT-PCR technique) were conducted as well. In addition, a Cycle Threshold (Ct) < 35 was defined as a positive.³

A total of 21 patients were included. Macroscopy revealed the presence of heavy edematous (1130 ± 349 g), hemorrhagic, and erythro-cyanotic lungs (ESD).

Microscopy revealed the presence of diffuse alveolar damage (DAD) in 20 cases (95%) (ESD).

In patients dead until day #10 (ICU stay), and in those dead between day #11 and day #20, the exudative stage was predominant and coexisted with proliferative elements and early fibrosis. In those patients who stayed at the ICU over 20 days, the proliferative pattern was predominant. Still exudative elements persisted being this pattern predominant in 2 cases (Fig. 1).

Pulmonary microvascular thrombosis was confirmed in 10 patients and predominant in those with ICU stays < 20 days (Fig. 1).

Lung tissue cultures tested positive in 17 cases (81%). In 6 cases (85%) cultures tested positive in patients with ICU stays up to 10 days. In another 6 (75%) cultures tested positive in patients with ICU stays between 11 and 20 days, and in 5 cases (83%) cultures tested positive in patients with ICU stays over 20 days. In the former, sensitive germs were found. However, after 20 days at the ICU, candida and extended-resistance and pandrug-resistant germs were isolated.⁴ *Aspergillus* was isolated in 2 cases (also seen in the AP examination) that turned out to be 2 cases of invasive pulmonary *Aspergillosis*.⁵

The SARS-CoV-2 viral load was analyzed in 17 patients. The samples showed high viral loads up to 30 days after symptom onset (ESD).

Anatomopathological findings revealed the presence of predominant DAD similar to what has been reported in patients with ARDS without SARS-CoV-2 infection. This is consistent with the findings made by Katzenstein et al.² who revealed a predominant exudative pattern within the first 10 days followed by proliferative elements and fibrosis from week #2.

However, the presence of exudative elements was the predominant pattern in some cases after 3 weeks of ICU stay, which is different compared to Katzenstein et al.'s findings² that limit this exudative stage within the first 15 days. This is consistent with the findings made by Thille who

found that 17% of lung autopsies had exudative patterns after 3 weeks. Similarly, cases with predominant proliferative changes within the first week of disease progression were found. This is consistent with the fact that proliferative stage can have a very early start.⁶

Another anatomopathological aspect we should mention is the frequency of pulmonary microthrombosis found in 50% of the cases. This has already been described in dead patients with SARS-CoV-2 infections.⁷ It is a phenomenon known as ARDS^{2,8} that can be observed early in the DAD setting, and is consistent with our findings where thrombosis was an early finding. Recently, Ackermann confirmed the presence of precapillary microthrombosis in patients with SARS-CoV-2 and H1N1 co-infection. However, the compromise of microthrombosis at the pulmonary capillary networks was 9 times higher in cases of SARS-CoV-2.⁷ This difference can explain the high degree of severe and refractory hypoxemia seen. Refractory hypoxemia amounts to 15% of all deaths due to non-SARS-CoV-2 induced ARDS⁸ while, in our series, it was directly responsible for 43% of all deaths reported.

A high percentage of positive cultures in patients with ICU stays of up to 10 days and resistant germs being isolated (consistent with the unit's ecology) was reported in the microbiological findings made in patients with prolonged ICU stays. The clinical significance of candida isolation in this group of patients is still pending assessment.

The viral load found in the lung tissue revealed high and persistent levels. This is consistent with what Schurink et al. described.⁹ However, it is different from the findings made by Merdji et al. who found no viral remains after the first week in lung samples obtained through biopsy punctures, which may explain the difference reported.¹⁰

Our study has some limitations. In the first place, it was conducted in only single center and the number of patients included was small. The strengths of the study were how fast autopsies were performed, which allowed microbiological examinations and analyses of the viral load found in lung tissues.

In conclusion, ARDS due to SARS-CoV-2 has an anatomopathological pattern characterized by DAD, which is similar to ARDS due to different etiologies. We confirmed the presence of a pattern with changes based on the time of evolution, although both the persistence and predomi-

nance of the exudative pattern in cases with > 30 days of evolution were significant. We should also mention the high prevalence of microthrombosis and how persistent the SARS-CoV-2 virus is in the lung parenchyma with high viral loads even in patients with prolonged disease.

References

1. Ranieri VM, Rubenfeld GD, Thompson BT, Ferguson ND, Caldwell E, Fan E, et al. ARDS Definition Task Force Acute respiratory distress syndrome: the Berlin Definition. *JAMA*. 2012;307:2526–33.
2. Katzenstein AL, Bloor CM, Leibow AA. Diffuse alveolar damage—the role of oxygen, shock, and related factors. A review. *Am J Pathol*. 1976;85:209–28.
3. Jefferson T, Spencer EA, Brasseley J, Heneghan C. Viral cultures for coronavirus disease 2019 infectivity assessment: a systematic review. *Clin Infect Dis*. 2021;73:e3884–99.
4. Jiménez Pearson MA, Galas M, Corso A, Hormazábal JC, Duarte Valderrama C, Salgado Marcano N, et al. Consenso latinoamericano para definir, categorizar y notificar patógenos multirresistentes, con resistencia extendida o panresistentes. *Rev Panam Salud Publica*. 2019;43:e65.
5. Ullmann AJ, Aguado JM, Arikan-Akdagli S, Denning DW, Groll AH, Lagrou K, et al. Diagnosis and management of Aspergillus diseases: executive summary of the 2017 ESCMID-ECMM-ERS guideline. *Clin Microbiol Infect*. 2018;24 Suppl 1:e1–38.
6. Thille AW, Esteban A, Fernández-Segoviano P, Rodríguez JM, Aramburu JA, Vargas-Errázuriz P, et al. Chronology of histological lesions in acute respiratory distress syndrome with diffuse alveolar damage: a prospective cohort study of clinical autopsies. *Lancet Respir Med*. 2013;1:395–401.
7. Ackermann M, Verleden SE, Kuehnel M, Haverich A, Welte T, Laenger F, et al. Pulmonary vascular endothelialitis, thrombosis, and angiogenesis in covid-19. *N Engl J Med*. 2020;383:120–8.
8. Montgomery AB, Stager MA, Carrico CJ, Hudson LD. Causes of mortality in patients with the adult respiratory distress syndrome. *Am Rev Respir Dis*. 1985;132:485–9.
9. Schurink B, Roos E, Radonic T, Barbe E, Bouman CSC, de Boer HH, et al. Viral presence and immunopathology in patients with lethal COVID-19: a prospective autopsy cohort study. *Lancet Microbe*. 2020;1:e290–9.
10. Merdji H, Mayeur S, Schenck M, Oulehri W, Clere-Jehl R, Cunat S, et al. Histopathological features in fatal COVID-19 acute respiratory distress syndrome. *Med Intensiva (Engl Ed)*. 2021;45:261–70.

F. Rodríguez^{a,*}, N. Nin^a, A. Fajardo^b, M. Auchayna^c, R. Guerediain^a, J. Hurtado^a

^a *Unidad de Medicina Intensiva, Hospital Español “Juan J Crottogini” ASSE, Montevideo, Uruguay*

^b *Laboratorio de Virología Molecular, Facultad de Ciencias, Universidad de la República, Montevideo, Uruguay*

^c *Laboratorio de Anatomía Patológica, Hospital Maciel ASSE, Montevideo, Uruguay*

Corresponding author.

E-mail address: fferrodd@gmail.com (F. Rodríguez).

2173-5727/ © 2022 Published by Elsevier España, S.L.U.

Prone position improves ventilation-perfusion mismatch in patients with severe acute respiratory distress syndrome



La posición prono mejora el desajuste ventilación-perfusión en pacientes con síndrome de distrés respiratorio agudo

Acute respiratory distress syndrome (ARDS) is a frequent condition in the intensive care unit (ICU).¹ It is clinically manifested by hypoxemic respiratory failure, airspaces flooding by inflammatory edema, and regional lung collapse due to “gas compression” of the dependent lung regions.² Hypoxemia is due to a ventilation/perfusion mismatch, especially in a heterogeneously ventilated and perfused lung.³ Prone positioning (PP) has shown to improve oxygenation and survival in selected ARDS patients. In addition, PP has been associated with recruiting of dorsal lung regions, with a more homogeneous ventilation and a reduction of pleural pressure gradient contributing with an improvement in the ventilation/perfusion (V/Q) ratio.^{4,5}

Electrical Impedance Tomography (EIT) is a bedside non-invasive monitoring tool of ventilation and perfusion distribution. Several studies have demonstrated EIT’s benefits in establishing ventilatory parameters and its role in assess the lung perfusion in ARDS.⁶ Thus, in this study we

aimed to analyze PP’s effects on the distribution of pulmonary ventilation and perfusion in patients with severe ARDS connected to mechanical ventilation (MV).

These data were presented preliminary as a poster in ESICM 2021.⁷

This is an observational sub-study of an already finished clinical study (Nº 170315007) which was conducted on patients admitted to the Intensive Care Department of the Hospital Clínico UC-Christus (Santiago, Chile), between November 2019 and March 2020 and required EIT as part of the ventilatory multimodal monitoring protocol. Considering that EIT perfusion measurements were indicated by attending physicians as an alternative diagnostic approach (i.e., thromboembolic disease), a waiver to use this data was requested to the ethical-scientific committee of the Pontificia Universidad Católica de Chile (Nº 210510004).

Patients with moderate to severe ARDS were included. PP was indicated by the attendant physician according to ICU protocols. The distribution of pulmonary ventilation and perfusion was evaluated with EIT (Enlight 1800, Timpel, São Paulo, Brazil) in the supine position (SP) and then in prone 2 h after proning. Impedance Ratio (IR) and Global Inhomogeneity (GI) indices were obtained from the EIT data, and arterial blood gases, hemodynamic parameters, and ventilatory mechanics were registered in each position.

The ventilation and perfusion maps delivered by EIT were divided into four regions of interest (quadrants), and in two gravitational regions (ventral and dorsal). For