



IMAGES IN INTENSIVE MEDICINE

Whispers of the heart: The journey of an aortic dissection

Susurros del corazón: la travesía de una disección aórtica

Pablo Carrión Montaner^{a,*}, Mario Sutil-Vega^a, Jordi Sans-Roselló^{a,b}

^a Servicio de Cardiología, Parc Taulí Hospital Universitari. Institut d'Investigació i Innovació Parc Taulí (I3PT), Universitat Autònoma de Barcelona, Sabadell, Spain

^b Departamento de Medicina, Facultad de Medicina, Universidad Autònoma de Barcelona, Barcelona, Spain

Available online 10 April 2025

A 47-year-old woman with a past medical history of bicuspid aortopathy in her paternal grandfather; her parents died young in a traffic accident. Due to palpitations, the outpatient echocardiogram performed revealed the presence of a dilated ventricle with a left ventricular end-diastolic diameter of 71 mm, indexed 3.4 mm/m², left ventricular ejection fraction of 55–60%, in addition to a bicuspid aortic valve with fusion between the right and left coronary cusps that triggered severe aortic regurgitation (Fig. 2) with an aortic root of 40 mm. A computed tomography scan was requested for preoperative study (Fig. 1), which was performed 3 weeks later, evidencing a Stanford/DeBakey type A aortic dissection I with an intimal flap at root level that extended longitudinally (Fig. 3) and spirally towards the left common iliac artery, involving the right brachiocephalic trunk without compromising its flow. In light of these findings, the patient was transferred to the cardiac intensive care unit for emergency surgery, undergoing David surgery with independent reimplantation of the brachiocephalic trunk.

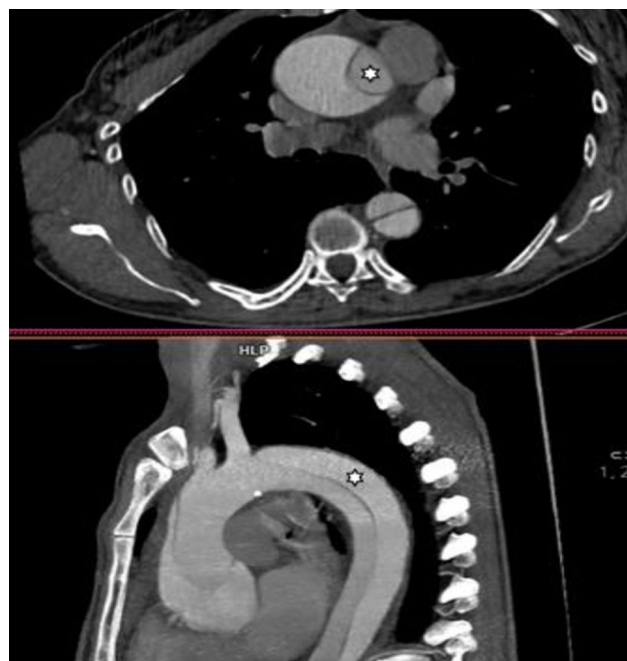

Figure 1

DOI of original article:

<https://doi.org/10.1016/j.medin.2025.502175>

* Corresponding author.

E-mail address: csv.pablo1@gmail.com (P. Carrión Montaner).

<https://doi.org/10.1016/j.medicine.2025.502175>

2173-5727/© 2025 Elsevier España, S.L.U. and SEMICYUC. All rights are reserved, including those for text and data mining, AI training, and similar technologies.

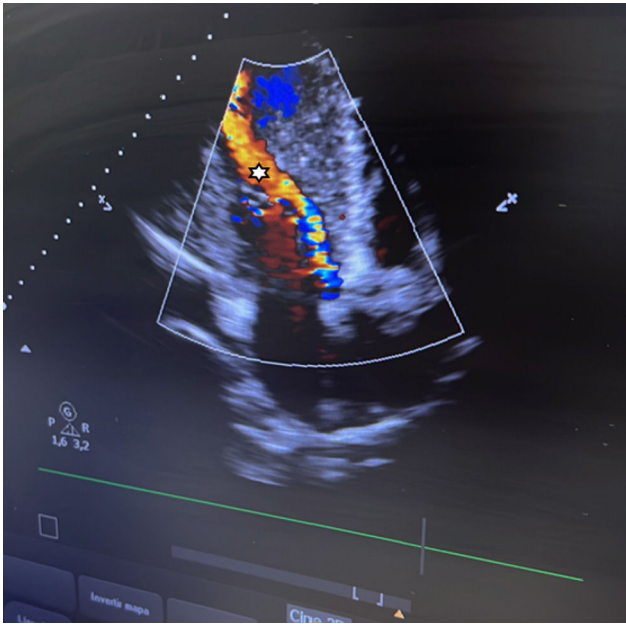


Figure 2

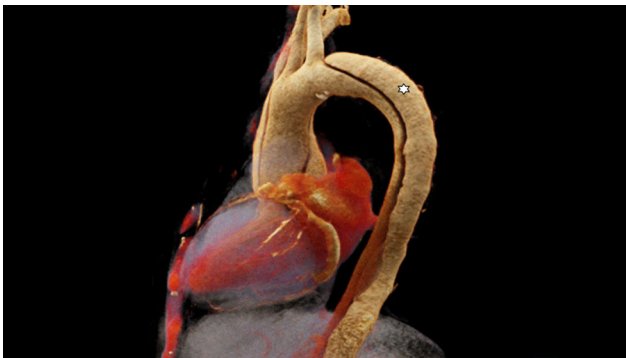

Figure 3

Funding

None declared.

Appendix A. Supplementary data

Supplementary material related to this article can be found, in the online version, at doi:<https://doi.org/10.1016/j.medine.2025.502175>.

Declaration of competing interest

None declared.