



IMAGES IN INTENSIVE MEDICINE

Pulmonary vein thrombosis following acute type aortic dissection



Trombosis venosa pulmonar después de la disección aórtica aguda de tipo a

Xiaoyang Zhou^a, Long Zhao^b, Bixin Chen^{a,*}

^a Department of Intensive Care Medicine, Ningbo No.2 Hospital, Ningbo, Zhejiang 315000, China

^b Department of Cardiovascular Surgery, Ningbo No.2 Hospital, Ningbo, Zhejiang 315000, China

Received 8 July 2024; accepted 11 August 2024

Available online 18 October 2024

A 66-year-old man with a history of hypertension presented to the emergency department with a 7-h history of severe chest pain. The patient was diagnosed with acute type A aortic dissection (ATAAD) and underwent urgent on-pump cardiac surgery. He started receiving low-dose anticoagulant therapy with 20 mg of enoxaparin twice per day on the 10th postoperative day. However, one week later, the patient suddenly developed hypoxemia but the hemodynamic state remained stable. Computed tomographic pulmonary angiography (CTPA) revealed normal pulmonary artery imaging and multiple filling defects in the left superior and inferior pulmonary veins (Fig. 1A and B, red arrows), indicating pulmonary vein thrombosis. The anticoagulant therapy was

strengthened, with the dose of enoxaparin increasing to 60 mg twice daily. After a two-week strengthened anticoagulation, a follow-up CTPA indicated that these pulmonary vein thrombi were dissipated (Fig. 1C and D, red arrows). This is the first report of pulmonary vein thrombosis following ATAAD which is a rare but potentially lethal condition.

Contribution of the authors

Zhou X, Zhao L, and Chen B participated in the patient's care, drafted the manuscript, and revised the manuscript. All authors read and approved the final manuscript.

DOI of original article: <https://doi.org/10.1016/j.medin.2024.08.008>

* Corresponding author.

E-mail address: nbsdeyyicu@163.com (B. Chen).

<https://doi.org/10.1016/j.medine.2024.09.011>

2173-5727/© 2024 Elsevier España, S.L.U. and SEMICYUC. All rights are reserved, including those for text and data mining, AI training, and similar technologies.

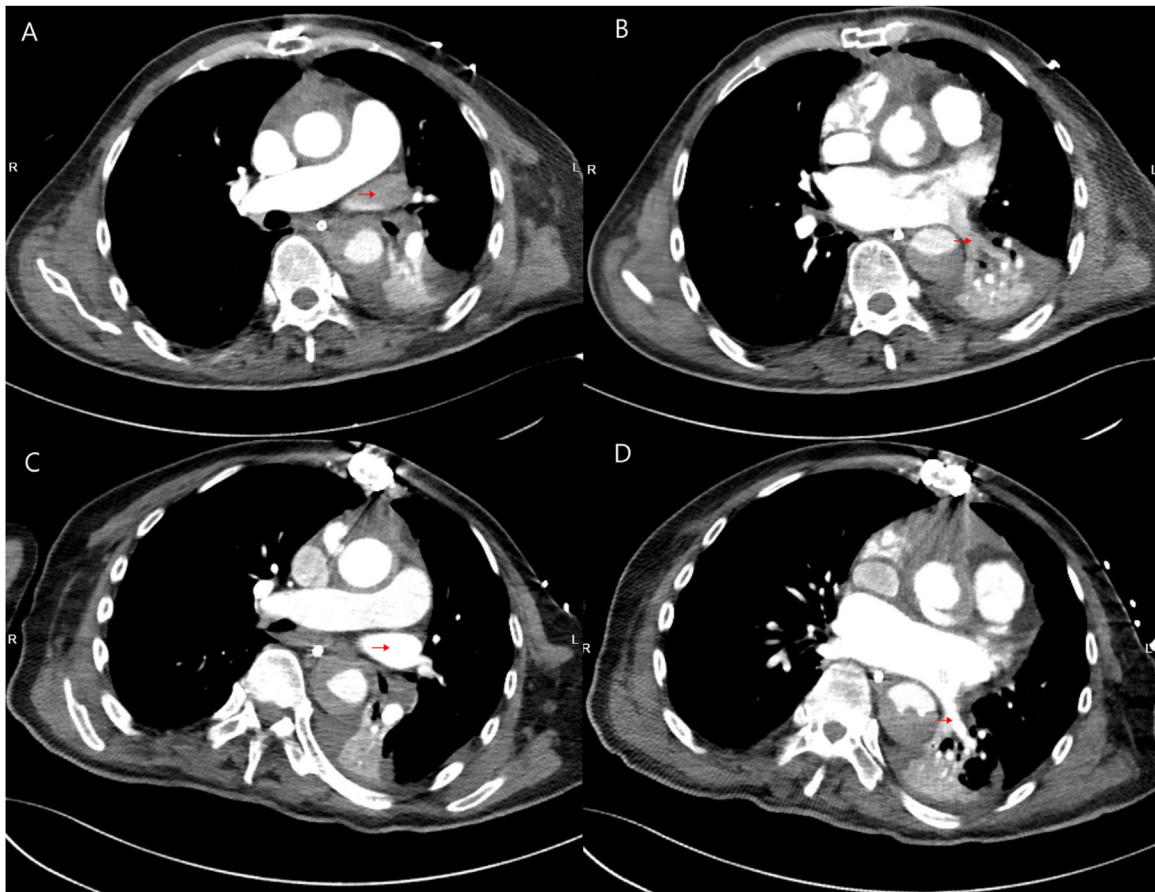


Figure 1

Funding

This work was supported by grants from the Zhejiang Medicine and Health Science and Technology Project (No. 2023KY1084, 2021KY1005) and the Project of NINGBO Leading Medical & Health Discipline (No. 2022-F16). The funders had no role in the study design, data collection, and analysis, decision to publish, or manuscript preparation.

Conflicts of interest

The authors declare that they have no potential conflict of interest.

Consent for publication

Written informed consent was obtained from the patient for publication of this article and any accompanying images.

Acknowledgments

None.