



IMAGES IN INTENSIVE MEDICINE

Diagnosis of colitis by ultrasound in an Intensive Care Unit

Diagnóstico de colitis por ecografía en una Unidad de Cuidados Intensivos

C.M. Marín Marín^{a,*}, P. García Moreno^b, R. Vicho Pereira^c

^a Servicio de Medicina Intensiva, Hospital General Universitario de Ciudad Real, Ciudad Real, Spain

^b Servicio de Medicina Intensiva, Hospital Universitario Marqués de Valdecilla, Santander, Spain

^c Clínica Rotger, Palma de Mallorca, Spain

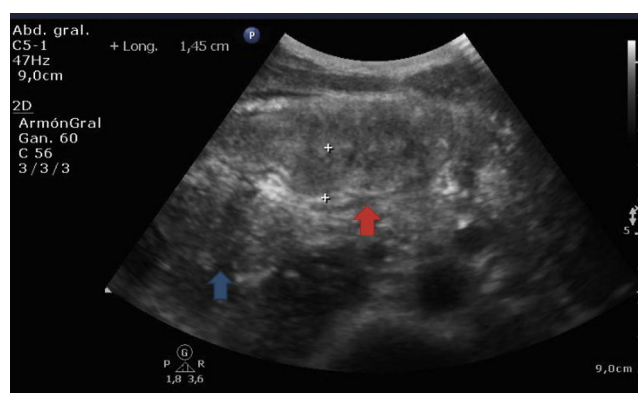


Figure 1

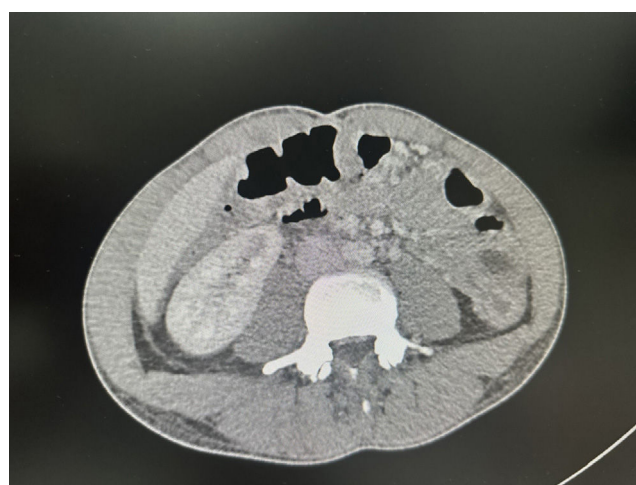

Figure 2

A 31-year-old man with no relevant past medical history was admitted with a several-day history of diarrhea, fever, and abdominal pain. Blood tests revealed the presence of leukocytosis and elevated CRP. The stool culture was positive for *Clostridium difficile* toxin.

DOI of original article: <https://doi.org/10.1016/j.medin.2024.502115>

* Corresponding author.

E-mail address: marinyamarin76@gmail.com (C.M. Marín Marín).

<https://doi.org/10.1016/j.medicine.2024.502115>

2173-5727/© 2024 Published by Elsevier España, S.L.U.

Please cite this article as: C.M. Marín Marín, P. García Moreno and R. Vicho Pereira, Diagnosis of colitis by ultrasound in an Intensive Care Unit, *Medicina Intensiva*, <https://doi.org/10.1016/j.medicine.2024.502115>

The abdominal ultrasound performed ([Fig. 1](#)) revealed the presence of inflammation of the wall of the large intestine (red arrow) with a thickness of 1.45 cm (normal value, 0.3 cm) and absence of peristalsis seen in the video, compared to the loop of the small intestine (blue arrow), which were findings consistent with colitis (later confirmed by CT scan [[Fig. 2](#)]).

Funding

None declared.

Declaration of competing interest

None declared.