

trombocitopenia, característica del HELLP, con la aparición de hipopituitarismo<sup>2</sup>.

La clínica puede aparecer de meses a años tras la agresión inicial; destacan: astenia, amenorrea, agalactia, hipoglucemia, hipotensión, intolerancia al frío y pérdida de vello púbico y axilar<sup>1,3</sup>. La cirugía, los traumatismos o las infecciones pueden precipitar o agravar los síntomas, favoreciendo la aparición de shock o de coma<sup>3</sup>, tal y como ocurrió en este caso, en el que la enferma pudo haber presentado una infección de vías respiratorias altas.

Lo relevante es el hecho de que el shock cardiogénico es una manifestación rara del síndrome de Sheehan<sup>4,5</sup>. Su mecanismo hormonal es poco conocido y se cree que intervienen distintos déficits, como la disminución de la GH y del IGF-1, la insuficiencia adrenal y el hipotiroidismo<sup>6,7</sup>. Estos déficits aparecen como consecuencia de la necrosis hipofisaria y, entre ellos, es el hipotiroidismo el más relacionado con la aparición del shock cardiogénico<sup>5,8,9</sup>. En nuestra paciente, la instauración del tratamiento con esteroides y levotiroxina consiguió una recuperación completa y rápida de la función miocárdica y de las arritmias.

Creemos, por tanto, que es importante resaltar que el síndrome de Sheehan debe ser considerado en el diagnóstico diferencial del shock cardiogénico en el puerperio, sobre todo si existen antecedentes de hemorragia uterina masiva periparto o de HELLP, dado que un tratamiento hormonal sustitutorio precoz favorece la pronta reversión del shock.

## Agradecimientos

Al Dr. Domínguez de Villota por su apoyo y dedicación al manuscrito y a otros aspectos de este trabajo.

## Bibliografía

1. Kovacs K. Sheehan syndrome. *Lancet*. 2003;361:520–2.

- Murao K, Imachi H, Muraoka T, Ishida T. Hemolysis elevated liver enzymes, and low platelet count (HELLP) syndrome with pituitary apoplexy. *Fertil Steril*. 2011;96:260–1.
- Dökmetaş HS, Kiliçli F, Korkmaz S, Yonem O. Characteristic features of 20 patients with Sheehan's syndrome. *Gynecol Endocrinol*. 2006;22:279–83.
- Laway BA, Alai MS, Gojwari T, Ganie MA, Zargar AH. Sheehan syndrome with reversible dilated cardiomyopathy. *Ann Saudi Med*. 2010;30:321–4.
- Bao SS, Fisher SJ. Repairing a broken heart with hormone replacement therapy: Case report of cardiogenic shock due to undiagnosed pituitary insufficiency. *Endocr Pract*. 2012;18:e26–31.
- Koga T, Sakamoto A, Kawazoe N, Sadoshima S, Onoyama K, Eto K. Adult reversible cardiomyopathy with pituitary adrenal insufficiency caused by empty sella: A case report. *Angiology*. 2000;51:319–23.
- Desai NR, Cheng S, Nohria A, Halperin F, Giugliano RP. Clinical problem-solving. When past is prologue. *N Engl J Med*. 2009;360:1016–22.
- Galli E, Pingitore A, Iervasi G. The role of thyroid hormone in the pathophysiology of heart failure: Clinical evidence. *Heart Fail Rev*. 2010;15:155–69.
- Klein I, Danzi S. Thyroid disease and the heart. *Circulation*. 2007;116:1725–35.

I. Fernández Simón<sup>a,\*</sup>, S. Alcántara Carmona<sup>a</sup>,  
R. Fernández Muñoz<sup>a</sup>, L. Martínez Álvarez<sup>a</sup>,  
C.J. Rodríguez<sup>b</sup>  
e I. Lipperheide Vallhonrat<sup>a</sup>

<sup>a</sup> Servicio de Medicina Intensiva, Hospital Universitario Puerta de Hierro, Majadahonda, Madrid, España

<sup>b</sup> Servicio de Radiodiagnóstico, Hospital Universitario Puerta de Hierro, Majadahonda, Madrid, España

\* Autor para correspondencia.

Correo electrónico: [m.i.f.simon@gmail.com](mailto:m.i.f.simon@gmail.com)  
(I. Fernández Simón).

<http://dx.doi.org/10.1016/j.medin.2013.04.002>

## Not too much hyperextension: Airway positioning using magnetic resonance imaging

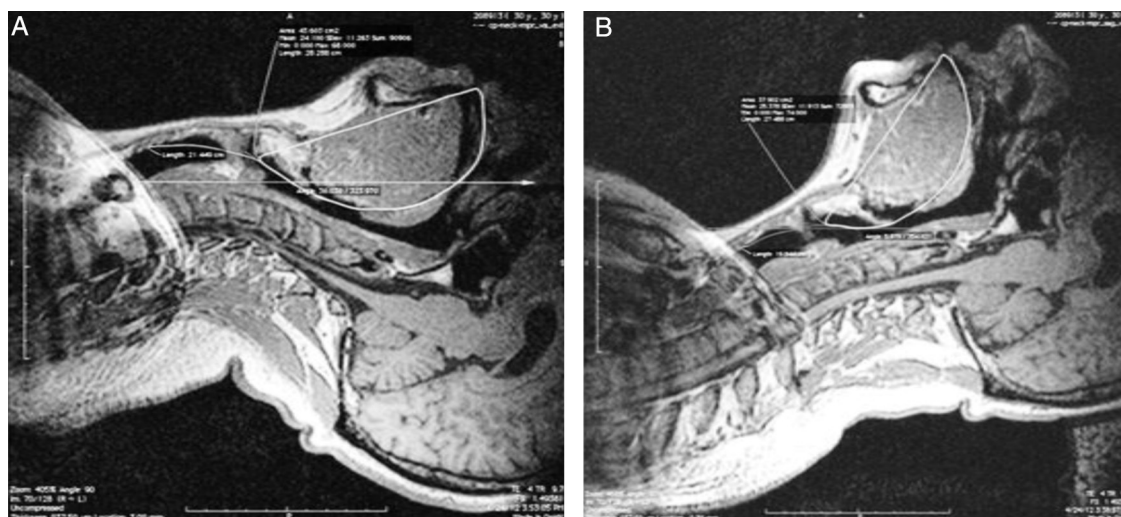
### No demasiada hiperextensión: posicionamiento de la vía aérea por medio de resonancia magnética nuclear

Airway management is of utmost importance to every anesthesiologist. The technique of choice is orotracheal intubation with direct laryngoscopy.<sup>1</sup> Determinants of orotracheal intubation include airway anatomical configuration and the type of devices and techniques used.<sup>2</sup> In 1897 Kirstein performed the first comparison between two positions for airway management. This comparison was followed by Chevalier Jackson's description of the neck extension and full hyperextension positions performed by his assistant during surgery in 1913. Magill

(1932) described that a patient during tracheal intubation adopts a position as if he/she were to sniff and Bannister and McBeth (1944) described the three-axes theory which postulates that an alignment of the oral, pharyngeal and laryngeal axes was necessary to achieve an adequate glottic opening.<sup>3</sup> However, a recent magnetic resonance imaging study on airway configuration suggests that such theory cannot be proven and proposes another method to assess objective measures for airway evaluation.<sup>4</sup>

Some studies have suggested that the use of an interscapular support with hyperextension improves airway configuration for laryngoscopy.<sup>1,5</sup> However, this position has never been compared to the generally accepted sniffing position described by Magill.<sup>6</sup>

The aim of this study was to compare airway configurations of healthy volunteers measured as  $\alpha$  angle and area under the line of site between the use of an interscapular support with hyperextension and sniffing positions. We



**Figure 1** Magnetic resonance imaging scans of a single volunteer. Panel A shows the interscapular support with hyperextension position and Panel B shows the sniffing position. The closed polygons depict the area between the oro-pharyngeal airway and the line of site ( $A = 43.60 \text{ cm}^2$ ,  $B = 37.90 \text{ cm}^2$ ). The intersection between a horizontal line and a line drawn at the point where the two curves intersect, define the angle  $\alpha$  ( $A = 33.03^\circ$ ,  $B = 5.97^\circ$ ).

wished to measure the differences of these two values between both positions.

After institutional and local ethics committee approval we performed six magnetic resonance imaging (MRI) studies on three healthy (no difficult airway risk factors) volunteers. Each volunteer was evaluated with both interscapular support with hyperextension and sniffing positions. T1-weighted images in the sagittal plane were obtained with a 1.5T Magnetom Vision MRI scanner (Siemens Medical Solutions, Erlangen, Germany). The interscapular support with hyperextension position was achieved by placing a 10 cm height and 8 cm width non-collapsible rubber device covered with silicone. The sniffing position was achieved by elevating the occiput 10 cm and extending the head at the atlanto-occipital joint. The images were analyzed with OsiriX 5.0.2 DICOM viewer for MacOS.

Two Bézier splines were measured as described by Greenland.<sup>4</sup> We used the slide that corresponded to the medial line as confirmed by both a radiologist and an otorhinolaryngologist. The splines were drawn starting at the tip of the top front incisors, through the middle of the airway passage, at the junction of the hard and soft palates, at the lever of the tip of the epiglottis, at the glottis, and the trachea at the level of the seventh vertical vertebra (Fig. 1). This created 2 curves, one that represents the

oro-pharyngeal airway (curving toward the right) and one that represents the pharyngo-glotto-tracheal airway (curving toward the left). A line was drawn at the point where the two curves met and the angle formed by this line and the horizontal one was calculated ( $\alpha$  angle). In addition, we measured the area between the first curve and a straight line that was drawn from the tip of the top front incisors to the middle of the glottis (representing the line of sight). The data from the two position groups were compared descriptively.

The results of the measurements of  $\alpha$  angle and area under the line of sight are shown in Table 1. These suggest that smaller angles and areas are obtained with the sniffing position as compared to the interscapular support with hyperextension position.

To our knowledge, the comparison between the sniffing and interscapular support with hyperextension positions had not been previously reported in the literature. In recent years, different studies have compared the sniffing position with other positions of the head and neck with apparently conflicting results.<sup>3,7,8</sup> The sniffing position has not been found to be superior to the simple extension of the neck during direct laryngoscopy in patients requiring elective surgery.<sup>9</sup> However, differences have been found when approaching obese patients and those with limited neck

**Table 1** Measurement results.

Volunteer	$\alpha$ angle ( $^\circ$ )		Area ( $\text{cm}^2$ )	
	Sniffing	Hyperextension	Sniffing	Hyperextension
1	6.79	29.86	25.83	38.22
2	16.02	32.65	37.74	39.29
3	5.97	33.03	37.90	43.60
4	2.70	26.64	37.71	39.64

movement. In one study of obese patients requiring bariatric surgery the ramped position had a better performance than the sniffing position.<sup>9-11</sup>

In conclusion, the use of an interscapular support with hyperextension position increases objective measures related to airway configuration. While these increases are not desirable for subjects without risk factors for difficult airway, it could provide an alternative approach for the management of the airway of obese patients.

### Funding disclosure

This study was carried out with funds of the Departments of Anesthesiology and Magnetic Resonance Imaging, Hospital de San Jose, Bogota.

### Conflicts of interest

The authors declare no conflicts of interest.

### Acknowledgments

We would like to honor the work of Astrid A Amezcua, MD, Faculty of Medicine, Fundación Universitaria de Ciencias de la Salud, Bogota, Colombia, who was part of the research team and who died during the course of this study. She participated in the design and analysis of this study, therefore she is considered as a coauthor.

### Bibliografía

1. Dhara S. Aids to tracheal intubation. *Anaesth Update*. 2003;17:3.
2. Carin A, Hagberg M. Conventional orotracheal and nasotracheal intubation in Benumof's Airway Management. 2nd ed. Philadelphia: Mosby; 2007.

3. Adnet F, Borron SW, Lapostolle F, Lapandry C. The three axis alignment theory and the sniffing position: perpetuation of an anatomic myth? *Anesthesiology*. 1999;91:1964-5.
4. Greenland KB, Edwards MJ, Hutton NJ, Challis VJ, Irwin MG, Sleigh JW. Changes in airway configuration with different head and neck positions using magnetic resonance imaging of normal airways: a new concept with possible clinical applications. *Br J Anaesth*. 2010;105:683-90.
5. Waldron S, Dobson A. A novel positioning technique to assist laryngoscopy in patients with a potentially difficult airway. *Eur J Anaesthesiol*. 2010;27:921.
6. Magill I. Endotracheal anesthesia. *Am J Surg*. 1936;34:450-5.
7. El-Orbany M, Woehlick H, Salem MR. Head and neck position for direct laryngoscopy. *Anesth Analg*. 2011;113:103-9.
8. Lee L, Weightman WM. Laryngoscopy force in the sniffing position compared to the extension-extension position. *Anaesthesia*. 2008;63:375-8.
9. Adnet F, Baillard C, Borron SW, Denantes C, Lefebvre L, Galinski M, et al. Randomized study comparing the sniffing position with simple head extension for laryngoscopic view in elective surgery patients. *Anesthesiology*. 2001;95:836-41.
10. Khorasani A, Candido KD, Saatee S, To Ghaleb AH. Sniff or not to sniff: that is the question. *Anesthesiology*. 2002;97:752-3.
11. Collins JS, Lemmens HJ, Brodsky JB, Brock-Utne JG, Levitan RM. Laryngoscopy and morbid obesity: a comparison of the sniff and ramped positions. *Obes Surg*. 2004;14:1171-5.

J.J. Arevalo<sup>a,b,c,\*</sup>, L.A. Muñoz<sup>a,b</sup>, A.M. Cardona<sup>a,b</sup>, B.R. Rosero<sup>a,b</sup>, L.E. Reyes<sup>a,b</sup>

<sup>a</sup> Faculty of Medicine, Fundación Universitaria de Ciencias de la Salud, Bogota, Colombia

<sup>b</sup> Department of Anesthesiology, Hospital de San Jose, Bogota, Colombia

<sup>c</sup> Research Division, Fundación Universitaria de Ciencias de la Salud, Bogota, Colombia

\* Corresponding author.

E-mail address: [jarevalo@fucsalud.edu.co](mailto:jarevalo@fucsalud.edu.co) (J.J. Arevalo).

<http://dx.doi.org/10.1016/j.medin.2013.05.002>

## Valor pronóstico intrahospitalario de la valoración funcional mediante el índice de Barthel en pacientes con síndrome coronario agudo: evaluación inicial de la enfermera en la unidad de cuidados intensivos cardiológicos

### In-hospital prognostic value of functional assessment using the Barthel index in patients with acute coronary syndrome: Initial evaluation of the nurse in the cardiac intensive care unit

Las personas de 65 o más años constituyen el grupo poblacional que presenta el crecimiento más rápido del mundo. En esta población, las enfermedades cardiovasculares constituyen la principal causa de muerte en los países desarrollados

y la segunda causa de deterioro funcional y pérdida de independencia<sup>1,2</sup>. Las personas mayores de 65 años se caracterizan por tener una mayor probabilidad de presentación atípica del síndrome coronario agudo (SCA), de comorbilidad y de polimedicación. Todo ello conlleva un elevado riesgo de presentar episodios adversos y una repercusión importante en la presión asistencial<sup>3</sup>. El índice de Barthel (IB) es una escala de valoración geriátrica para cuantificar el grado de dependencia que presenta un paciente. Recientemente, nuestro grupo demostró que el IB fue una variable predictora independiente de la duración de la estancia media hospitalaria en pacientes con SCA que ingresaron en la unidad de cuidados intensivos cardiológicos (UCIC)<sup>4</sup>. El objetivo del presente trabajo fue evaluar la influencia de la valoración funcional sobre la mortalidad intrahospitalaria, en pacientes mayores de 65 años que ingresan por SCA.

Presentamos un estudio prospectivo de pacientes mayores de 65 años que ingresaron en la UCIC con el diagnóstico de SCA con y sin elevación del segmento ST. Se