

La mayoría de los pacientes asocian lesiones; las más comunes son las fracturas costales, seguidas del neumotórax. El examen físico nos puede guiar en el diagnóstico (hematoma supraclavicular, pulso alterado, soplo). Karmy-Jones et al.³ describen una serie de 8 pacientes, donde el principal signo de sospecha fue el ensanchamiento mediastínico, observado en la radiografía de tórax. La arteriografía es el «gold standar» para su diagnóstico, aunque la angio-TC nos ofrece suficiente información para llevarlo a cabo (disección, dilatación aneurismática, pseudoaneurisma, hematomas, trombos intraluminales, signos de sangrado activo), así como para su manejo posterior⁴.

El cuanto al tratamiento médico en la fase inicial, es necesario un control estricto de la TA, para lo cual es preciso un buen control del dolor (perfusión de opiáceos), y fármacos antihipertensivos (betabloqueantes intravenosos: labetalol, esmolol), y tan pronto sea posible, iniciar la anticoagulación si no existen contraindicaciones⁵.

Los pacientes con una disección simple, sin un hematoma circundante extenso, pueden ser manejados de forma conservadora¹. La reparación de la arteria innominada incluye los siguientes procedimientos:

- Quirúrgico: la reparación primaria de la lesión mediante sutura simple, si técnicamente es factible, en pacientes con desgarras parciales. En la mayoría de los casos, las lesiones de la arteria innominada se manejan mediante un baipás (técnica de exclusión); este enfoque permite la angioplastia y la interposición del injerto, sin el uso de heparinización sistémica, baipás cardiopulmonar o parada circulatoria hipotérmica¹.
- Endovascular: los stents se utilizaron inicialmente para el tratamiento de los aneurismas de la aorta. Estudios recientes están demostrando el papel de los stents en el tratamiento de las lesiones aórticas traumáticas. Las ventajas incluyen el menor daño fisiológico y la no necesidad de heparinización, que nos permite tratar enfermos con trauma grave hasta un mejor control de las lesiones asociadas; las desventajas, el fallo del dispositivo, sobre todo dependiendo de la localización de la lesión⁶.

Como conclusión, la lesión de la arteria innominada tras un traumatismo es infrecuente, pero potencialmente mortal, que requiere tratamiento quirúrgico. En las lesiones aisladas, la intervención precoz está recomendada. En pacientes con traumatismo grave, el retraso intencional de

la reparación hasta la estabilización de las lesiones asociadas está justificado (baja probabilidad de rotura de un pseudoaneurisma de la arteria innominada con un adecuado control de la TA).

Conflicto de intereses

Los autores declaran no tener ningún conflicto de intereses.

Agradecimientos

A la Unidad de Trauma y Emergencias del Servicio de Medicina Intensiva.

Bibliografía

1. Stover S, Holtzman RB, Lottenberg L, Bass TL. Blunt innominate artery injury. *Am Surg.* 2001;67:757-9.
2. Hirose H, Gill IS. Blunt injury of proximal innominate artery. *Ann Thorac Cardiovasc Surg.* 2004;10:130-2.
3. Karmy-Jones R, DuBose R, King S. Traumatic rupture of the innominate artery. *Eur J Cardiothorac Surg.* 2003;23:782-7.
4. Azarcon F, Ghaleb M. Early diagnosis and treatment of a post-traumatic pseudoaneurysm/dissection of the innominate artery. *Prehosp Disaster Med.* 2014;29:209-11.
5. Symbas JD, Halkos ME, Symbas PN. Rupture of the innominate artery from blunt trauma: Current options for management. *J Card Surg.* 2005;20:455-9.
6. Paukovits TM, Lukács L, Bérczi V, Hirschberg K, Nemes B, Hüttel K. Percutaneous endovascular treatment of innominate artery lesions: A single-centre experience on 77 lesions. *Eur J Vasc Endovasc Surg.* 2010;40:35-43.

L.J. Terceros-Almanza^{a,*}, J. Barea-Mendoza^a,
M. Chico-Fernández^a, C. García-Fuentes^a,
V. Navarro-Cutillas^b y E. Alted-López^a

^a Unidad de Trauma y Emergencias, Servicio de Medicina Intensiva, Hospital Universitario 12 de Octubre, Madrid, España

^b Servicio de Radiología, Hospital Universitario 12 de Octubre, Madrid, España

* Autor para correspondencia.

Correo electrónico: luchoter000@hotmail.com
(L.J. Terceros-Almanza).

<http://dx.doi.org/10.1016/j.medin.2014.12.005>

Atypical hemolytic uremic syndrome in intensive care: Case report in an adult



Síndrome hemolítico urémico atípico en cuidados intensivos: caso clínico de un adulto

Dear Editor,

Thrombotic microangiopathy (TMA) is a pathologic process characterized by inflammation and thickening of

wall vessels, endothelial edema, basement membrane detachment, intimal fibrosis and platelet thrombi formation with occlusion of vascular lumen. It affects mainly kidney and central nervous system microvasculature¹; depending on the lesion distribution, two different syndromes are described: Thrombotic Thrombocytopenic purpura (TTP) and hemolytic uremic syndrome (HUS). Both are characterized by microangiopathic hemolytic anemia and thrombocytopenia.^{2,3} Neurological disorders are dominant in TTP whereas renal failure is dominant in HUS.

HUS is denominated *typical* (90% of the cases) when caused by enteric shiga toxin-producing microorganisms, as

Escherichia coli serotype O157:H7. The other rare cases are classified as *atypical (aHUS)*, due to alternate complement pathway deregulation, or *secondary* to conditions such as pregnancy, autoimmune disease, invasive pneumococcal infections, HIV and H1N1 infections, cancer, malignant hypertension, and certain drugs.^{1,2}

Most aHUS cases have a strong genetic component involving mutations and polymorphisms in the complement proteins genes.⁴ It is more common in children and young adults and the prognosis is poor with high morbidity and mortality in acute phase and 50% of progression to chronic kidney disease.¹

The authors describe the case of a 35-year-old man who presented at the emergency department with fever, abdominal pain, nausea, bilious vomiting and decrease urine output for two weeks. He denied diarrhea and revealed history of intravenous drug abuse, under methadone program.

At admission he was pale, with icteric sclera, hypertensive (197/108 mmHg) and tachypneic. Biochemistry revealed: normocytic normochromic anemia (Hb 6 g/dL); platelet count $132 \times 10^9 L^{-1}$, acute kidney injury (Urea 81 mmol/L; Creatinine 1487 $\mu\text{mol/L}$); high Lactate dehydrogenase (LDH 23 $\mu\text{kat/L}$) and proteinuria (100 mg/dL). In the following hours the patient developed agitation, hallucinations and respiratory failure due to aspiration of gastric content, for what he was intubated and mechanically ventilated.

At the Intensive Care Unit he presented thrombocytopenia (platelets 98×10^9), severe kidney impairment with anuria and started hemodialysis. The anemia study revealed hemolysis: schistocytes in peripheral blood smear, haptoglobin <7 mg/dL and raised LDH (26.7 $\mu\text{kat/L}$), and the patient underwent regular blood transfusion, during the first week. TMA diagnosis was admitted and daily plasmapheresis was initiated, with exchange of 1.5 plasma volume per session. He completed a total of eleven sessions, with renal function recovery, allowing the spacing of dialysis sessions, as well as normalization of platelets count and LDH levels.

Complementary laboratory study excluded malignant hypertension, autoimmunity diseases, HIV and H1N1 infection. Shiga toxin was negative, C3 factor decreased, with no other changes in complement factors or respective antibodies. The activity of ADAMTS13 was normal without anti-ADAMTS13 antibodies (Table 1). The total body CT-scan excluded neoplasia. Kidney biopsy showed histopathological features of thrombotic microangiopathy (Fig. 1) and the genetic screening revealed a mutation in factor H.

During the hospitalization the patient presented high blood pressure, requiring labetalol perfusion followed by various antihypertensive agents. On the seventh day, he was successfully extubated. As infectious complications, he had *Staphylococcus epidermidis* bacteremia and *Stenotrophomonas maltophilia* on sputum smear, both resolved with the appropriate antibiotherapy.

At the time of discharge, the platelet count was $275 \times 10^9/L$, LDH 4.48 $\mu\text{kat/L}$, Urea 27.8 mmol/L, Creatinine 223.6 $\mu\text{mol/L}$. Due to the persistence of kidney dysfunction the patient was transferred to nephrology ward where he continued on hemodialysis and started treatment with eculizumab, in the dosis of 900 mg weekly in the first month, followed by 1200 mg every 2 weeks thereafter.

Table 1 Complementary laboratory study.

Blood, urine and bronchial cultures	Negative
Shiga toxin	Negative
HIV antibodies	Negative
H1N1 (PCR)	Negative
<i>Streptococcus pneumoniae</i> and <i>Legionella pneumophila</i> urine antigen	Negative
Antistreptolysin-O (ASO) titers	Negative
Complement study	
C3 factor	0.48 g/L [0.9–1.8]
C4, CHF, CHB, CHI	Normal
Anti-ADAMTS13 antibodies	Negative
ADAMTS13 activity	73% (normal >6%)
ANA, anti-dsDNA, anti-Sm, anti-SSA (Ro), anti-SSB (La), anti-RNP, anti-cardiolipine, anti-beta-2 glycoprotein I, anti-phospholipid antibodies	Negative
Serum protein electrophoresis	Normal

HIV: Human immunodeficiency virus; PCR: polymerase chain reaction; CFH: factor H; CFI: factor I; CFB: factor B; ADAMTS13: a desintegrin and metalloprotease with thrombospondin type1 domain 13; ANA: antinuclear antibody; dsDNA: double-stranded DNA; Sm: Smith; SSA: Sjögren syndrome A; SSB: Sjögren syndrome B; RNP: ribonucleic protein.

Hemolytic anemia, thrombocytopenia and acute renal failure as initial presentation were suggestive of TMA most likely HUS due to the magnitude of renal impairment. Subsequent finding of a regular ADAMTS13 activity excluded TTP.⁵ Absence of diarrhea on presentation, negative Shiga toxin made less probable typical HUS diagnosis. Moreover, drugs and pathological conditions that cause secondary HUS were excluded.

Atypical HUS associated with genetic or immune complement abnormalities was the most probable hypothesis. Activation of the alternative complement pathway with low serum C3, normal C4 and Factor B as well as absence of anti-factor H antibodies and normal levels of Factor H and I indicated a possible mutation in genes encoding C3, factor H or factor I,⁶ that was confirmed by the genetic screening.

Mutation in factor H was first identified in 1973 and it courses with low or normal plasma levels of factor H.⁶ It is the most frequent genetic abnormality in aHUS patients (20–30%) and is associated with 50–70% risk of death or end stage renal disease in the first episode (<1 year) with a 50% risk of relapse and 75–90% risk of recurrence after kidney transplantation.⁶

Initial approach of aHUS requires red blood cells transfusion and hemodialysis, which were promptly initiated in this case. Platelet transfusion is contraindicated despite thrombocytopenia, except in cases of active bleeding, since it may exacerbate TMA.⁶ Plasma therapy is the classical first choice treatment for all cases of aHUS.^{1,2,6} Plasmapheresis is preferred to plasma infusion because it assures the delivery of functional complement regulatory proteins and the removal of dysfunctional factors, with lower risk of volume overload.

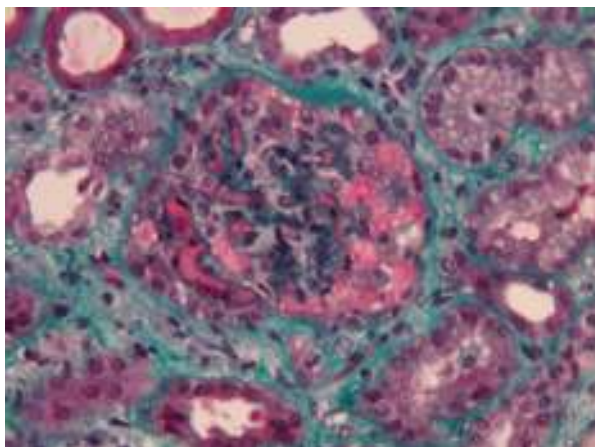


Figure 1 Renal Biopsy (green masson trichromium stain) 400× – marked glomerular capillary stasis – glomerular thrombus.

Should be initiated as early as possible, with exchange of 1.5 plasma volume per session, and continued until platelet count, hemoglobin, and LDH levels normalization.^{1,5-7}

Plasmapheresis has been the cornerstone of aHUS treatment since 1980 and was the only therapy available until 2010. A recent therapeutic alternative is eculizumab – a humanized monoclonal IgG antibody which binds to the C5 complement protein preventing the formation of C5b-9 (membrane attack complex) – already approved by the EMA and FDA.^{1,2,4,6} Two prospective phase II trials have demonstrated its efficacy on improving the platelet count and renal function of aHUS patients, including those with progressing TMA and those with long-standing, substantial kidney damage.⁸ A posterior analysis confirmed the persistence of the clinical benefits after two years of follow-up.⁹ Eculizumab was also associated with significant improvements in health-related quality of life.⁸

Barriers to eculizumab use include patient safety concerns, as infection with encapsulated bacterial organisms and the elevated cost.² On the other hand no cumulative toxicity or unexpected serious infections were observed, and survival was 100% on pivotal prospective studies,⁸⁻¹⁰ turning Eculizumab into a very promising option for aHUS patients treatment.

Funding

None.

Conflict of interest

None.

Bibliografía

1. Campistol Plana JM, Arias M, Ariceta Iraola G, Blasco M, Espinosa M, Grinyó JM, et al. Actualización en síndrome hemolítico urémico atípico: diagnóstico y tratamiento. Documento de consenso. Nefrol publicación Of la Soc Española Nefrol. 2013;33:27–45. Available from: <http://dialnet.unirioja.es/servlet/articulo?codigo=4119823&info=resumen&idioma=SPA>
2. Nester CM, Thomas CP. Atypical hemolytic uremic syndrome: what is it, how is it diagnosed, and how is it treated? Hematology Am Soc Hematol Educ Program. 2012;2012:617–25. Available from: <http://www.ncbi.nlm.nih.gov/pubmed/23233643>
3. Ruggenti P, Cravedi P, Remuzzi G. Thrombotic microangiopathies, including hemolytic uremic syndrome. In: Floege J, Johnson R, Feehaly J, editors. Comprehensive clinical nephrology. Fourth ed. Missouri: Elsevier Saunders; 2010. p. 344–51.
4. Rodríguez de Córdoba S, Hidalgo MS, Pinto S, Tortajada A. Genetics of atypical hemolytic uremic syndrome (aHUS). Semin Thromb Hemost. 2014;40:422–30.
5. Salvadori M, Bertoni E. Update on hemolytic uremic syndrome: diagnostic and therapeutic recommendations. World J Nephrol. 2013;2:56–76. Available from: <http://www.pubmedcentral.nih.gov/articlerender.fcgi?artid=3832913&tool=pmcentrez&rendertype=Abstract>
6. Loirat C, Frémeaux-Bacchi V. Atypical hemolytic uremic syndrome. Orphanet J Rare Dis. 2011;6:60. Available from: <http://www.orjrd.com/content/6/1/60>
7. Taylor CM, MacHin S, Wigmore SJ, Goodship THJ. Clinical practice guidelines for the management of atypical haemolytic uraemic syndrome in the United Kingdom. Br J Haematol. 2010;148:37–47.
8. Legendre CM, Licht C, Muus P, Greenbaum LA, Babu S, Bedrosian C, et al. Terminal complement inhibitor eculizumab in atypical hemolytic-uremic syndrome. N Engl J Med. 2013;368:2169–81. Available from: <http://www.nejm.org/doi/abs/10.1056/NEJMoa1208981>
9. Licht C, Greenbaum LA, Muus P, Babu S, Bedrosian CL, Cohen DJ, et al. Efficacy and safety of eculizumab in atypical hemolytic uremic syndrome from 2-year extensions of phase 2 studies. Kidney Int. 2015;87:1061–73. Available from: <http://www.nature.com/doi/10.1038/ki.2014.423>
10. Keating G. Eculizumab: a review of its use in atypical haemolytic uraemic syndrome. Drugs. 2013;73:2053–66.

I. Agudo, T. Souto-Moura*, L. Azevedo, R. Cavaco, N. Germano, L. Bento

Unidade de Urgência Médica, Hospital de São José, Centro Hospitalar de Lisboa Central, EPE, Lisboa, Portugal

* Corresponding author.

E-mail address: teresasoutomoura@gmail.com

(T. Souto-Moura).

<http://dx.doi.org/10.1016/j.medin.2015.09.007>