



IMAGES IN INTENSIVE MEDICINE

Central bronchial reflex finding in pulmonary infarct Hallazgo de reflejo central bronquial en el infarto pulmonar



R. Blancas*, D. Ballesteros-Ortega, Ó. Martínez-González

Servicio de Medicina Intensiva, Hospital Universitario del Tajo, Universidad Alfonso X El Sabio, Spain

Available online 21 July 2016

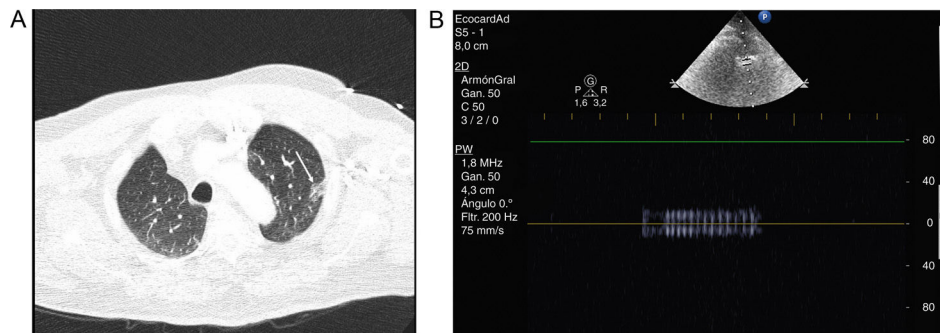


Figure 1

Central bronchial reflex is a sign of pulmonary infarction explored by pulmonary ultrasound. This finding appears in late pulmonary infarction as an expression of bronchial constriction and compression due to surrounding edema and pulmonary bleeding.

We present a case of massive pulmonary embolism with pulmonary infarction. The patient was on mechanical ventilation due to right heart failure and severe hypoxemia. Pulmonary CT showed in the lung parenchyma an area of triangular morphology in peripheral location with increased density and frosted glass appearance compatible with pulmonary infarction on the left upper lobe (Fig. 1, Panel A, arrow). Over the same location, central bronchial reflex is seen as a hyperechoic structure surrounded by hypoechoic tissue on ultrasound exam. Bronchus can be identified by pulsed-Doppler, showing the flow of gas insufflated by ventilator (Fig. 1, Panel B).

Funding

This work has been done without any funding.

Conflicts of interest

The authors declare no conflict of interest.

* Corresponding author.
E-mail address: rafael.blancas@salud.madrid.org (R. Blancas).