



IMAGES IN INTENSIVE MEDICINE

Cerebral circulatory arrest detected by insonation of extracranial arteries



Paro circulatorio cerebral detectado mediante la insonación de arterias extracraneales

P. Blanco

Intensive Care Physician, Intensive Care Unit, Hospital "Dr. Emilio Ferreyra", Necochea, Argentina

Received 22 June 2016; accepted 2 July 2016
Available online 7 December 2016

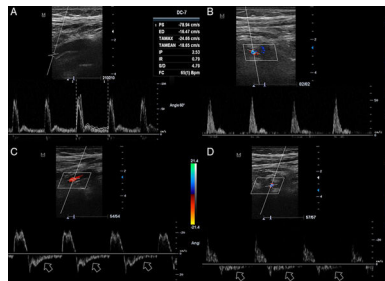


Figure 1

Transcranial doppler (TCD) is able to detect cerebral circulatory arrest (CCA), aiding in confirming the clinical diagnosis of brain death (BD). However, approximately 15% of patients lack optimal bone windows for TCD evaluation. At this instance, intensivists should consider that evaluation of the extracranial arteries in the neck can display the same CCA patterns as interrogation of intracranial arteries. A 54-year-old female patient with history of obesity and arterial hypertension was admitted in coma to the ICU shortly after suffering a massive brainstem hemorrhage. No signs of BD were demonstrated at admission. TCD was not able to recognize intracranial arterial flow due to a lack of optimal bone windows. Doppler interrogation of bilateral internal carotid (ICA) and vertebral artery (VA) in the neck using a linear probe were used to demonstrate the progression of waveforms from a high pulsatility, not corresponding to CCA (Fig. 1A and B), to a reverberating pattern, demonstrated by retrograde diastolic flow (arrows) (Fig. 1C and D), over an observing period of 16 h, corresponding to CCA and fully coexisting with the clinical criteria for diagnosing BD.

Acknowledgments

The author would like to thank Mrs. Julieta Vigna for the language guidance.

E-mail address: ohusabes@gmail.com

<http://dx.doi.org/10.1016/j.medin.2016.07.006>

0210-5691/© 2016 Elsevier España, S.L.U. y SEMICYUC. All rights reserved.