



IMAGES IN INTENSIVE MEDICINE

Hamman's syndrome in a child Síndrome de Hamman en un niño

Y.A. Kamal

Department of Cardiothoracic Surgery, Faculty of Medicine, Minia University, El-Minia, Egypt

Available online 22 November 2019

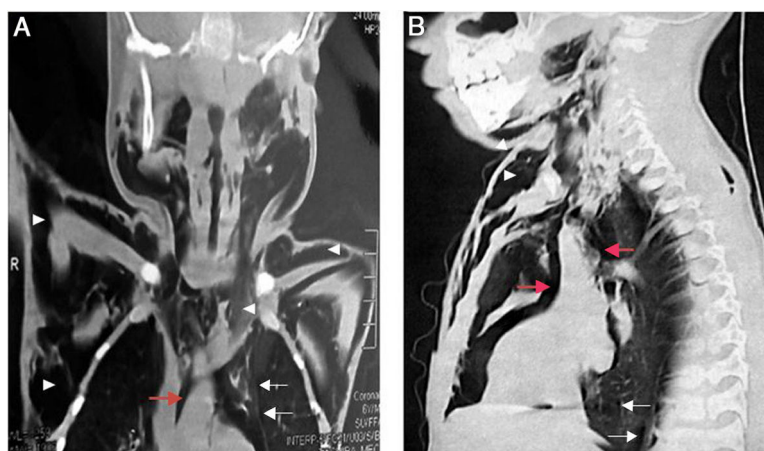


Figure 1

A 5-year-old boy presented to the emergency department with sudden progressive swelling of the neck, without a history of trauma or medical disease. On examination, there was a crepitus over the neck and upper chest wall. A crunching sound synchronous with the heartbeat was auscultated at the left sternal border ([Supplementary file](#), [Audio waveform](#)). Computed tomography (CT) showed an extensive subcutaneous emphysema (Fig. 1A and B, arrowheads), pneumomediastinum (Fig. 1A and B, red arrows), and interstitial air dissection known as Macklin's effect (Fig. 1A and B, white arrows). The findings on CT were consistent with the diagnosis of Hamman's syndrome associated with spontaneous rupture of alveoli. The condition improved after decompression of the subcutaneous emphysema with cervical skin incision, and the patient was discharged on the fifth day of admission.

Funding

None declared.

Conflict of interests

The authors declare no conflict of interest.

Appendix A. Supplementary data

Supplementary data associated with this article can be found, in the online version, at [doi:10.1016/j.medin.2019.09.012](https://doi.org/10.1016/j.medin.2019.09.012).

E-mail addresses: yaser.ali.kamal@yahoo.com, Yasser.Ali@mu.edu.eg

<https://doi.org/10.1016/j.medin.2019.09.012>

0210-5691/© 2019 Elsevier España, S.L.U. y SEMICYUC. All rights reserved.