



## IMAGES IN INTENSIVE MEDICINE

### Meningeal empyema

### Empiema meningeo

N.A. Gemelli\*, N.M. Ciarrocchi, E. San Roman

Adult Intensive Care Department, Hospital Italiano de Buenos Aires, Argentina

Available online 21 January 2020

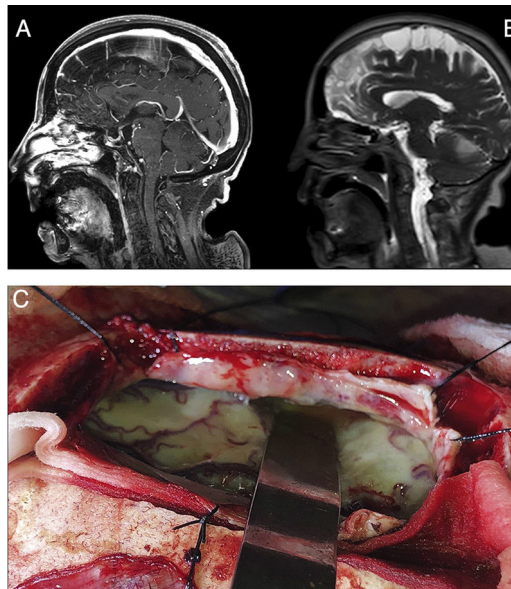


Figure 1

A 72-year-old female patient with history of high blood pressure presented to the emergency with right hemiparesis, aphasia and seizures. Brain computed tomography did not find hemorrhagic lesions and brain magnetic resonance imaging showed no vascular lesions but revealed laminar subdural collection in the right parietal convexity with restriction on the diffusion sequence together with multiple areas of restriction in the subarachnoid space on the bihemispheric convexity (Fig. 1, Panel A and B). It evolved with Glasgow coma scale 8/15, fever and saturation 87% due to aspiration, proceeding to endotracheal intubation. Blood cultures and lumbar puncture were performed. It showed glucose 49 mg/dl (serum glucose 484 mg/dl), protein level of 946 g/dl, leukocytes 3744/mm<sup>3</sup> (95% neutrophils), 1.000 erythrocytes/mm<sup>3</sup>. Blood and cerebrospinal fluid cultures revealed the presence of *Streptococcus pneumoniae*. Neurosurgical intervention was decided with craniectomy and drainage of meningeal empyema (Panel C). The patient completed 8 weeks of ceftriaxone with good clinical outcome.

\* Corresponding author.

E-mail address: [nicolas.gemelli@hospitalitaliano.org.ar](mailto:nicolas.gemelli@hospitalitaliano.org.ar) (N.A. Gemelli).