



IMAGES IN INTENSIVE MEDICINE

Vegetation with a lizard-tail appearance in the left atrium



Vegetación en forma de cola de lagarto en aurícula izquierda

M. Chicot^a, A. Sarraj^b, E. Aguilar^b, D.A. Rodríguez^{a,*}

^a Servicio de Medicina Intensiva, Hospital Universitario de La Princesa, Madrid, Spain

^b Servicio de Cirugía Cardíaca, Hospital Universitario de La Princesa, Madrid, Spain

Received 14 March 2016; accepted 17 April 2016

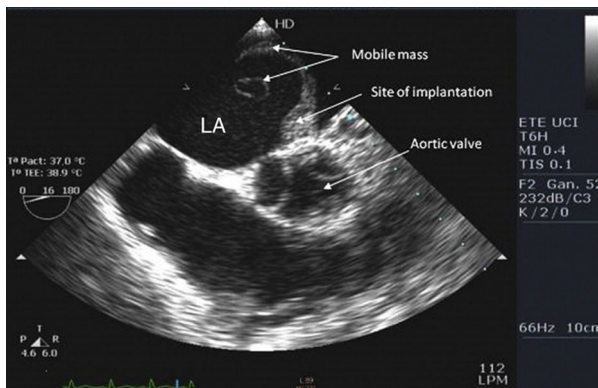


Figure 1

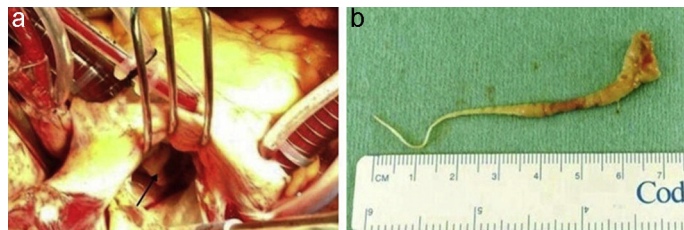


Figure 2

We present the case of a 77-year-old woman with infective endocarditis due to methicillin-sensitive *Staphylococcus aureus*. Transesophageal echocardiography revealed a very large mobile vegetation with a tail-like appearance (Fig. 1). It grew from the internal wall of the left atrium adjacent to the anterior commissure and caused severe mitral valve insufficiency. Daptomycin and cloxacillin were started and the patient underwent mitral valve replacement. The mass was excised completely together with the mitral valve. Macroscopical examination showed an 8 cm-long purulent lizard's tail-shaped growth (Fig. 2a and b). Anticoagulation was started on day 3 after surgery but was interrupted due to evidence of intracranial hemorrhage. On day 37, the patient was transferred to the general ward without neurological sequelae and subsequently discharged home without further complications.

Conflicts of interest

The authors declare no conflict of interest.

* Corresponding author.

E-mail address: cancabrilla@hotmail.com (D.A. Rodríguez).