

observation, we believe the association (without speaking of causality as such) to be plausible.

In conclusion, in young individuals, immobility at home during lockdown due to the COVID-19 pandemic could have been associated to an increased risk of PTE. In the event of a new outbreak of the pandemic, we must bear this possibility in mind, and the public health services should recommend physical exercise at home. In future, particularly if working from home (telecommuting) becomes consolidated as an occupational option, we must take this serious disease condition and its prevention into account.

Financial support

The present study has received no financial support.

Conflicts of interest

The authors declare that they have no conflicts of interest.

References

1. Tapson VF. Acute pulmonary embolism. *N Engl J Med*. 2008;358:1037–52, <http://dx.doi.org/10.1056/NEJMra072753>.
2. Helms J, Tacquard C, Severac F, Leonard-Lorant I, Ohana M, Delabranche X, et al. High risk of thrombosis in patients with severe SARS-CoV-2 infection: a multicenter prospective cohort study. *Intensive Care Med*. 2020;46:1089–98, <http://dx.doi.org/10.1007/s00134-020-06062-x>.
3. Ackermann M, Verleden SE, Kuehnel M, Haverich A, Welte T, Laenger F, et al. Pulmonary vascular endothelialitis, thrombosis, and angiogenesis in Covid-19. *N Engl J Med*. 2020;383:120–8, <http://dx.doi.org/10.1056/NEJMoa2015432>.
4. Di Nisio M, van Es N, Büller HR. Deep vein thrombosis and pulmonary embolism. *Lancet*. 2016;388:3060–73, [http://dx.doi.org/10.1016/S0140-6736\(16\)30514-1](http://dx.doi.org/10.1016/S0140-6736(16)30514-1).
5. Lapostolle F, Surget V, Borron SW, Desmaizières M, Sordelet D, Lapandry C, et al. Severe pulmonary embolism associated with air travel. *N Engl J Med*. 2001;345:779–83, <http://dx.doi.org/10.1056/NEJMoa010378>.

6. Beasley R, Raymond N, Hill S, Nowitz M, Hughes R. eThrombosis: the 21st century variant of venous thromboembolism associated with immobility. *Eur Respir J*. 2003;21:374–6, <http://dx.doi.org/10.1183/09031936.03.00039403>.
7. Lippi G, Mattiuzzi C, Favaloro EJ. e-thrombosis: epidemiology, physiopathology and rationale for preventing computer-related thrombosis. *Ann Transl Med*. 2018;6:344, <http://dx.doi.org/10.21037/atm.2018.09.03>.
8. Aldington S, Pritchard A, Perrin K, James K, Wijesinghe M, Beasley R. Prolonged seated immobility at work is a common risk factor for venous thromboembolism leading to hospital admission. *Intern Med J*. 2008;38:133–5, <http://dx.doi.org/10.1111/j.1445-5994.2007.01597.x>.
9. Healy B, Levin E, Perrin K, Weatherall M, Beasley R. Prolonged work- and computer-related seated immobility and risk of venous thromboembolism. *J R Soc Med*. 2010;103:447–54, <http://dx.doi.org/10.1258/jrsm.2010.100155>.
10. Huo Yung Kai S, Ferrières J, Carles C, Turpin M, Lapébie FX, Dutheil F, et al. Lower limb venous and arterial peripheral diseases and work conditions: systematic review [published online ahead of print, 2020 May 21]. *Occup Environ Med*. 2020, <http://dx.doi.org/10.1136/oemed-2019-106375>, oemed-2019-106375.

D. Franch-Llasat^a, E. Mayor-Vázquez^a, J. Pedregosa-Díaz^b, M. Herrero-Redondo^c, X. Ortin-Font^d, F. Roche-Campo^{a,*}

^a Servicio de Medicina Intensiva, Hospital Verge de la Cinta, Tortosa, Tarragona, Spain

^b Servicio de Laboratorio Clínico ICS Camp de Tarragona i Terres de l'Ebre, Tarragona, Spain

^c Servicio de Radiodiagnóstico, Unidad IDI-Terras de l'Ebre, Hospital Verge de la Cinta, Tortosa, Tarragona, Spain

^d Servicio de Hematología, Hospital Verge de la Cinta, Tortosa, Tarragona, Spain

* Corresponding author.

E-mail address: ferranroche@gmail.com (F. Roche-Campo).

2173-5727/ © 2020 The Author(s). Published by Elsevier España, S.L.U. All rights reserved.

SARS-CoV-2 or *Pneumocystis jirovecii*? A case report[☆]



¿SARS-CoV-2 o *Pneumocystis jirovecii*? A propósito de un caso

Dear Editor:

The most common site of infection in immunocompromised oncological children is the lungs.¹ The difficulties involved in achieving an early diagnosis are associated with its atypical presentation. Neutropenia reduces the inflammatory processes leading to lower clinical and radiological

expressions.² Therefore, some of these patients, like our case, can get worse while they are recovering from neutropenia.

The radiological presentation of pulmonary infiltrates can help achieve the differential diagnosis.^{1–3} The most common bacteria include *Streptococcus pneumoniae*, *Staphylococcus*, and *Haemophilus influenzae*. However, in these patients, infections due to opportunistic bacteria should also be taken into consideration like *Pseudomonas spp.* and viral agents being the most common of all respiratory viruses¹ and in the case of permanent neutropenias, fungal infections, being *Candida* the most common of all² including *Aspergillus*.

This is the case of a 4-year-old kid of 15 kg of weight diagnosed back on January 29th, 2020 of acute lymphoblastic leukemia type B without any other significant past medical history. He was administered prednisone (60 mg/m²/day) followed by chemotherapy (the patient received his last dose on March 19).

[☆] Please cite this article as: González Moyano AB, Medina Ramos L, del Cañizo Moreira M, Merino de Lucas E, González Lorenzo M, Esteban García-Fontecha M. ¿SARS-CoV-2 o *Pneumocystis jirovecii*? A propósito de un caso. *Med Intensiva*. 2021;45:124–126.

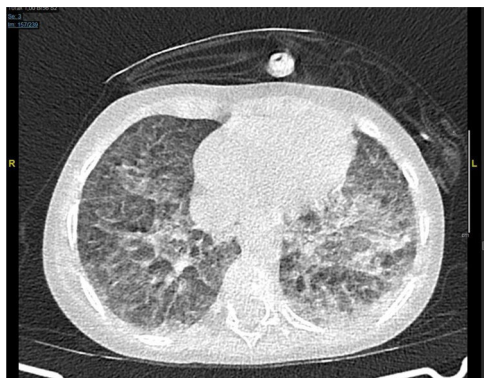

Figure 1 Thoracic CT scan with bilateral ground-glass opacities.

Four days later he was admitted to the Day Hospital with signs of fever of 100.4°F and pancytopenia (420 leukocytes/ μ L and 40 neutrophils/ μ L). At home he remained asthenic but still without a fever. He was admitted to the pediatric oncology unit and administered cefepime (150 mg/kg/day) followed by prophylactic cotrimoxazole.

After 2 days and due to the presence of persistent fever the patient was administered teicoplanin (10 mg/kg/day) plus amphotericin B (5 mg/kg/day). The hemocultures, urine culture, and PCR run to identify the presence of influenza virus and respiratory syncytial virus all tested negative.

The patient progressed with respiratory failure and required a nasal cannula. The thoracic x-ray performed revealed the opacification of left hemithorax consistent with an inflammatory-infectious process.

Therefore, pneumonia in aplastic patient is suggested in the epidemiological context of infection due to new coronavirus infection in his grandfather (who remains hospitalized), mother, and grandmother as confirmed on the polymerase chain reaction (PCR) test performed through nasopharyngeal aspirate swab obtained using the Cobas 6800 system (Roche). The PCR performed to discard the presence of coronavirus at admission had tested negative. After the positive diagnosis of the patient's mother and grandmother, he is tested again after the thoracic x-ray and the PCR tests negative one more time.

Nonetheless, due to the patient's clinical worsening and epidemiological situation it is decided to administer azithromycin (10 mg/kg/day), hydroxychloroquine (100 mg every 12 h within the first day followed by 50 mg every 12 h starting on day 2) followed by lopinavir/ritonavir 2.25 mL every 12 h.

The next day the respiratory failure worsens despite the bone marrow aplasia recovery and a thoracic CT scan is performed that reveals the presence of both pseudonodular ground-glass opacities and bilateral peripheral opacities (Fig. 1).

High-flow oxygen therapy is started at 12 lmp and a FiO₂ of 35%. The patient remains with persistent fever, tachypnea, subcostal retraction, and his admission to the pediatric ICU is authorized.

Initially, high-flow oxygen therapy is maintained while increasing parameters with good tolerance. However, the patient shows work of breathing with universal retraction and desaturation, and it is decided to proceed with oro-

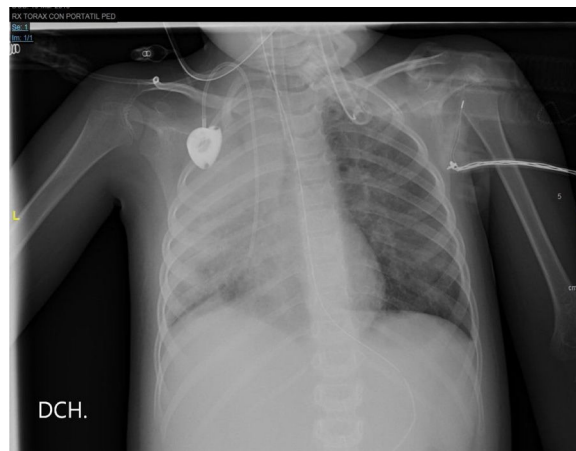


Figure 2 Thoracic x-ray.

tracheal intubation and connection to invasive mechanical ventilation. A new PCR test to discard the presence of SARS-CoV-2 in bronchial aspirate is run again but it tests negative once again. Lopinavir/ritonavir, azithromycin, and cefepime are all withdrawn and meropenem (60 mg/kg/day) is administered.

The respiratory pathogens panel test (IgM and IgG antibodies against *Legionella pneumophila*, *Mycoplasma pneumoniae*, and *Chlamydia pneumoniae*), the galactomannan antigen blood test, and the viral load of cytomegalovirus all tested negative; no further serology tests of such control panel were run.

The thoracic x-ray performed the next day confirmed the complete opacification of the right lung with left paracardiac infiltration (Fig. 2).

The blood test performed at the ICU admission confirmed the following parameters: C-reactive protein (CRP), 11.9 mg/dL; procalcitonin (PCT), 2.63 ng/mL; triglycerides, 250 mg/dL; lactate dehydrogenase, 780 U/L; ferritin, 1734 μ L/L; interleukin 6, 105 pg/dL; lymphopenia, 750/ μ L; platelets, 70 000/ μ L, and D-dimer 2.72 μ g/mL. The CRP, PCT, triglyceride, and lactate dehydrogenase levels dropped gradually, ferritin levels went up to 2016 μ L/L on day 2, and IL-6 levels reached 141 pg/dL on day 3 without further determinations. Lymphopenia and thrombocytopenia recovered on day 4 while D-dimer levels remained stable.

Due to these findings, the epidemiological situation, the situation of progressive respiratory failure, and the radiological images obtained, the case was discussed with the Unit of Infectious Diseases. It was decided to administer tocilizumab 8 mg/kg in a single dose and run a total antibody test looking for the presence of IgM, IgG, and IgA antibodies against SARS-CoV-2 (two-step chemiluminescent immunoassay, Elecsys anti-SARS-CoV-2, Roche), and a new PCR in plasma (500 mL of plasma mixed with the same amount of lysis solution) and in feces (fecal suspension in 500 mL of physiological serum using the same procedure as in plasma processed using the Cobas 6800 system (Roche). Everything tested negative.

The next day, the PCR test to discard *Pneumocystis jirovecii* in bronchial aspirate tested positive and cotrimoxazole was titrated to therapeutic doses.

The patient's respiratory condition started to improve, and he was extubated on day 8. The patient was discharged from the ICU and transferred to the hospital pediatric oncology unit. He showed eupneic breathing upon return to room air with oral tolerance to monotherapy with cotrimoxazole. The patient received no corticoids during his ICU stay.

A month later, the antibody test against the new coronavirus was run again but it tested negative one more time.

In light of the 2 diagnostic possibilities of our case, we were facing an epidemiological context with great exposure to SARS-CoV-2, compatible radiological and analytical findings, but negative test samples without ever running a PCR test in bronchoalveolar lavage (that performs better) or a rectal swab.⁴ We should not forget that inflammatory parameters are not specific of this infection. However, high levels of IL-6 and PCR are actually considered independent risk factors for its severity.^{5,6} High procalcitonin levels are suggestive of bacterial over-infection.⁷ In this case its discrete elevation was considered an acute-phase reactant. *Pneumocystis* is an environmental fungus that can cause false positive results.⁸ However, its diagnosis could not be excluded since we saw refractory infiltrates in the patient that did not respond to therapy within the first 24–72 h. Still, the response to therapy was faster than expected.

References

- Bosque M, Elorz J, Villar M. Pulmón en el paciente neutropénico posquimioterapia. *Complicaciones respiratorias en el niño inmunodeprimido y en el niño oncológico*. 328-333. *Protoc diagn ter pediatr*. 2017;1:321–42 www.aeped.es/protocolos/.
- García Salido A, Nieto Moro M, Casado Flores J. Dificultad respiratoria en el niño con cáncer. *Med Intensiva* [Internet]. 2011;35:562–8. Available from: <http://scielo.isciii.es/scielo.php?>
- Fernandez-Delgado R, Escribano A, Donat J. Paciente neutropénico. Mesa redonda SENP. *El pulmón en el paciente inmunodeprimido*. *An Pediatr*. 2004;60 supl 1:24–6. Available from: <https://www.analesdepediatria.org/>
- Li J, Feng J, Liu TH, Xu FC, Song GQ. An infant with a milk SARS-CoV-2 infection detected only by anal swabs: a case report. *Braz J Infect Dis*. 2020. Epub ahead of print. PMID: 32389618; PMCID: PMC7200387. www.elsevier.com/locate/bjid [consultado abril 2020].
- Zhu Z, Cai T, Fan L, Lou K, Hua X, Huang Z, Gao G. Clinical value of immune-inflammatory parameters to assess the severity of coronavirus disease 2019. *Int J Infect Dis*. 2020;95:332–9. <http://dx.doi.org/10.1016/j.ijid.2020.04.041>.
- Ruggiero A, Romano A, Attinà G. Covid-19 and children with cancer: are they at increased risk of infection? *Pediatr Res*. 2020. <http://dx.doi.org/10.1038/s41390-020-0919-1>.
- Lippi G, Plebani M. Procalcitonin in patients with severe coronavirus disease 2019 (COVID-19): a meta-analysis. *Clin Chim Acta*. 2020;505:190–1. <http://dx.doi.org/10.1016/j.cca.2020.03.004>.
- Fauchier T, Housseine L, Garo-Toussaint M, Casanova V, Marti PM, Pomares C. Detection of *Pneumocystis jirovecii* by Quantitative PCR To Differentiate Colonization and Pneumonia in Immunocompromised HIV-Positive and HIV-Negative Patients. *J Clin Microbiol*. 2016. <http://dx.doi.org/10.1128/JCM.03174-1ht88> <https://pubmed.ncbi.nlm.nih.gov/27008872/>.

A.B. González Moyano^{a,*}, L. Medina Ramos^a,
M. del Cañizo Moreira^b, E. Merino de Lucas^c,
M. González Lorenzo^a, M. Esteban García-Fontecha^a

^a *Medicina Intensiva, Hospital General Universitario de Alicante, Alicante, Spain*

^b *Oncología Infantil, Hospital General Universitario de Alicante, Alicante, Spain*

^c *Unidad de Enfermedades Infecciosas, Hospital General Universitario de Alicante, Alicante, Spain*

* Corresponding author.

E-mail address: anabelengmoyano@gmail.com
(A.B. González Moyano).

2173-5727/ © 2020 Elsevier España, S.L.U. and SEMICYUC. All rights reserved.