



IMAGES IN INTENSIVE MEDICINE

Acute respiratory failure secondary to massive laryngeal papillomatosis[☆]



Insuficiencia respiratoria aguda secundaria a papilomatosis laríngea masiva

A. Ruiz Martínez^{a,*}, A. Zabalegui Pérez^a, P. Saiz-Lopez^b

^a Servicio de Medicina Intensiva, Hospital Universitario de Burgos, Burgos, Spain

^b Servicio de Anatomía Patológica, Hospital Universitario de Burgos, Burgos, Spain

Available online 24 June 2022

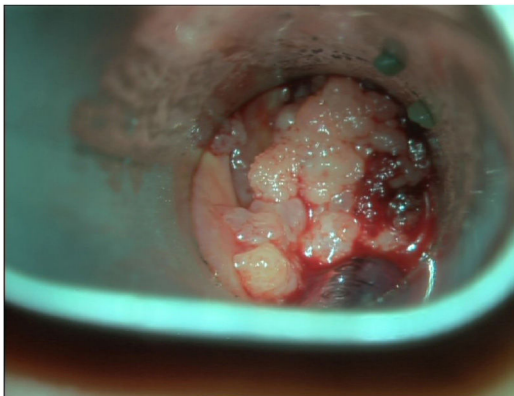


Figure 1

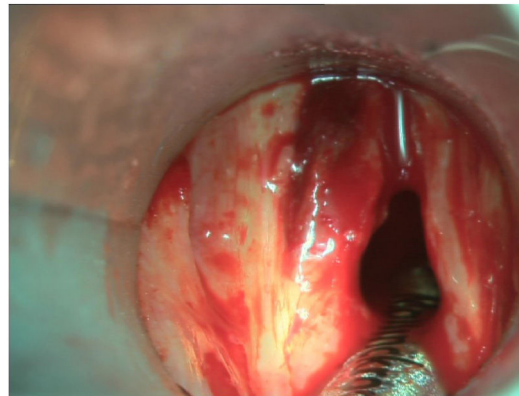


Figure 2

A Nicaraguan woman with no relevant disease history presented with sudden onset dyspnea, laryngeal stridor and basal SatO₂ 75%. Urgent laryngoscopy evidenced an exophytic mass of soft consistency. Orotracheal intubation under videolaryngoscopic (C-MAC[®]) guidance was performed, displacing the mass with the orotracheal tube, without incidents. At subsequent surgery, multiple

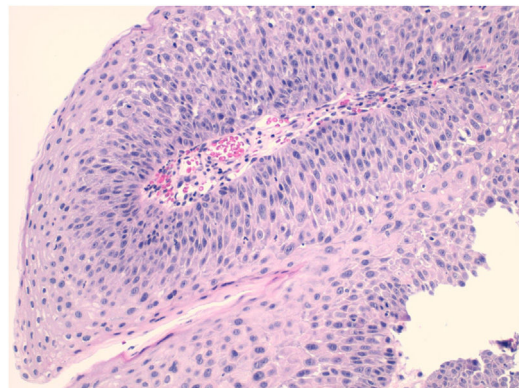


Figure 3

[☆] Please cite this article as: Ruiz Martínez A, Zabalegui Pérez A, Saiz-Lopez P. Insuficiencia respiratoria aguda secundaria a papilomatosis laríngea masiva. Med Intensiva. 2022;46:546–547.

* Corresponding author.

E-mail address: audberto.ruiz@gmail.com (A. Ruiz Martínez).

supra- and subglottic papillomatous implants were removed (Fig. 1), with posterior good airway patency (Fig. 2). Evaluation of esophageal and bronchial tree spread proved negative. The diagnosis was confirmed by the subsequent histopathological study (Fig. 3).

Laryngeal papillomatosis is a rare disorder caused by the human papillomavirus (HPV), producing severe respiratory

failure. Urgent surgery is indicated, and the prognosis is good – though recurrences are frequent. In the event of recurrence, repeat surgery combined with immunomodulating therapy such as intralesional interferon, should be considered.